

## CASE REPORT

# Leiomyosarcoma in a Posthysterectomy Patient

<sup>1</sup>Meenu Agarwal, <sup>2</sup>Sujay Hegde, <sup>3</sup>Naina Sawapure

## ABSTRACT

Leiomyosarcoma is an aggressive soft tissue sarcoma derived from smooth muscle cells. Uterus is the commonest location for a leiomyosarcoma. They may either arise de novo from uterine musculature or the connective tissue of uterine blood vessels, or in a pre-existing benign leiomyoma and are associated with poor outcome. A 45 year patient presented with mass per abdomen. She had undergone laparoscopic hysterectomy three years back for menorrhagia. A provisional diagnosis of ovarian neoplasm was made based on the ultrasonography and CT scan report, but tumour markers were negative. Staging laparotomy was done, mass removed in toto, infracolic omentectomy, appendectomy and bilateral ureteric dissection was done. Post operatively, patient recovered well. Histopathological analysis was suggestive of leiomyosarcoma FNCLCC grade 3. Patient was advised radiation and is on regular follow up with the oncosurgeon.

**Keywords:** Hysterectomy, Laparoscopy, Leiomyosarcoma.

**How to cite this article:** Agarwal M, Hegde S, Sawapure N. Leiomyosarcoma in a Posthysterectomy Patient. *Int J Gynecol Endsc* 2017;1(1):50-52.

**Source of support:** Nil

**Conflict of interest:** None

## INTRODUCTION

Uterine sarcomas as a group are uncommon cancers, representing approximately 8% of all uterine malignancies<sup>1</sup>; of these, 42 to 60% are of the leiomyosarcoma subtype.<sup>2</sup> Uterine leiomyosarcomas are aggressive, heterogeneous cancers associated with high rates of progression and recurrence and poor outcome. The rarity of the disease, however, has not hampered research efforts to study its etiology and discover newer interventions.

Uterine leiomyosarcoma is most often discovered by chance when a woman has a hysterectomy performed for fibroids. Usually women present with abnormal vaginal bleeding, palpable pelvic mass, and pelvic pain.

Laparoscopic hysterectomies are increasingly popular because of the morcellated tissue remaining after the short recovery period of patients after total laparoscopic hysterectomy, causing short hospital stays and reducing health care costs. Several studies have reported intra-abdominal pieces.

## CASE REPORT

A 45-year-old P3L3 posthysterectomized patient presented in casualty on January 30, 2017, with complaints of abdominal fullness and discomfort since 2 years, bloating sensation after meals and loss of appetite since 2 months. She was P3L3 with all vaginal deliveries and normal menstrual history previously. She underwent total laparoscopic hysterectomy + bilateral salpingectomy + left oophorectomy for menorrhagia 3 years back and histopathological analysis suggestive of endometrium in proliferative phase, normal myometrium, chronic nonspecific cervicitis, changes of hydrosalpinx in fallopian tube, and simple cyst in the ovary. There was no report of any morcellation done during the last surgery.

On examination vitally, she was stable and a large mass occupying whole of the abdomen with irregular borders and firm consistency was felt.

On admission, ultrasonography was done s/o posthysterectomy status, large solid cystic mass of 22 × 19 × 16 cm arising from pelvis posterior to urinary bladder, extending into lower abdomen above umbilical level. It was compressing posterior wall of urinary bladder laterally extending up to lateral pelvic walls and compressing right ureter with proximal hydroureteronephrosis in right kidney s/o right ovarian mass lesion.

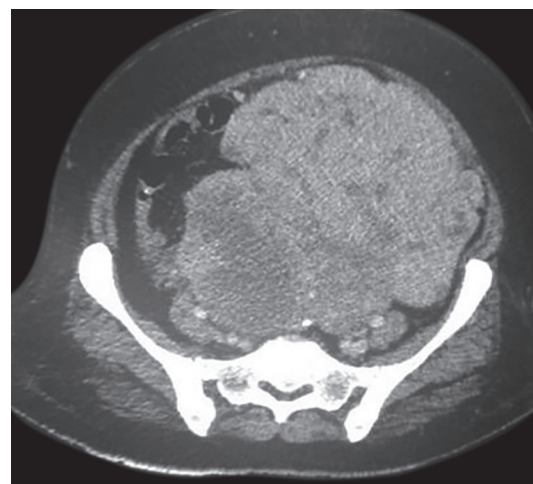


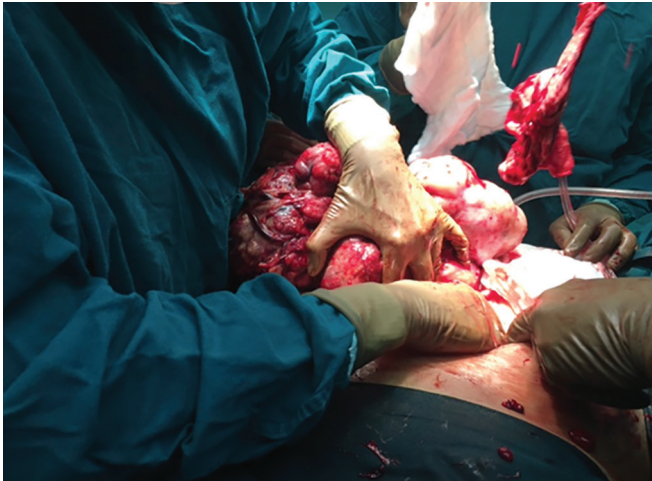Fig. 1: CT-scan of the abdomen and pelvis

<sup>1</sup>Senior Consultant, <sup>2</sup>Oncosurgeon, <sup>3</sup>Resident

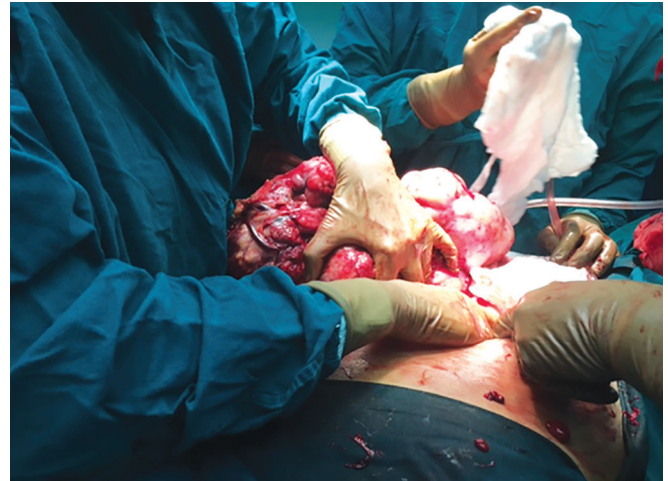<sup>1,3</sup>Department of Obstetrics and Gynecology, Ruby Hall Clinic Pune, Maharashtra, India

<sup>2</sup>Department of Surgical Oncology, Ruby Hall Clinic Pune, Maharashtra, India

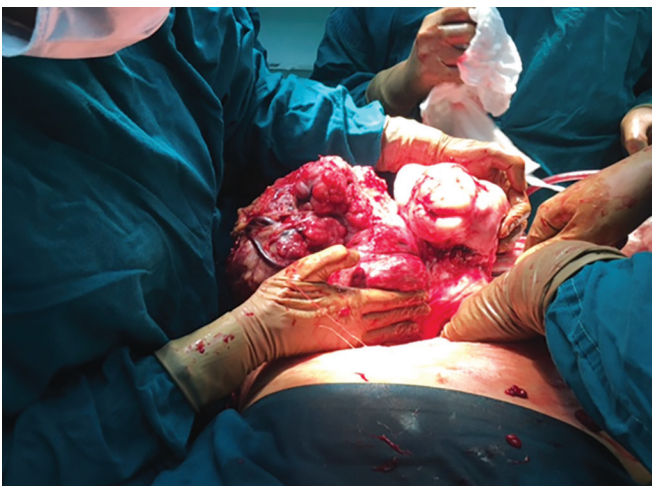**Corresponding Author:** Meenu Agarwal, Senior Consultant Department of Obstetrics and Gynecology, Ruby Hall Clinic Pune, Maharashtra, India, Phone: +919822036970, e-mail: drmjainagarwal@hotmail.com



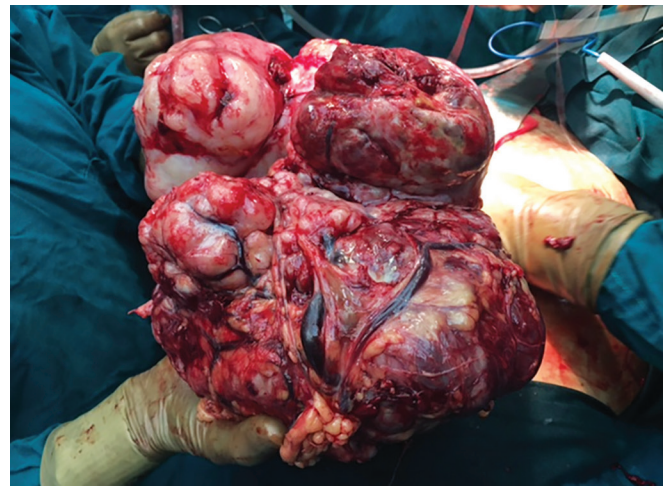
**Fig. 2:** Laparotomy done with a midline vertical incision



**Fig. 3:** Large irregular mass occupying the whole of abdomen



**Fig. 4:** Mass adherent to lateral pelvic wall lifted finding a plane manually



**Fig. 5:** Highly vascular mass removed *in toto*

Ca-125 was 40.13, carcinoembryonic antigen 1.3, and alpha-fetoprotein 1.4.

The computed tomographic scan of abdomen and pelvis was done on January 31, 2017 (Fig. 1). A large heterogeneously enhancing solid mass lesion of  $17 \times 19 \times 26$  cm with central necrotic areas was seen in pelvis posterosuperior to the urinary bladder, laterally reaching up to both pelvic walls, superiorly extending into abdomen predominantly on left side in umbilical and left lumbar region and displacing bowel loops superiorly and the right lateral aspect.

Anterosuperiorly, mass is seen beneath the anterior abdominal wall. Anteroinferiorly, it was causing mass effect on posterior wall of urinary bladder, posteriorly causing severe compression of the distal sigmoid colon and proximal rectum with suspicious loss of fat planes with the rectum and adjacent fat planes.

The lesion was also causing lateral displacement of bilateral mid and lower ureter right more than left, causing mild hydronephrosis on right side.

The patient underwent staging laparotomy on February 1, 2017 (Fig. 2). Intraoperatively, bilateral double J stenting was done. A large irregular mass  $30 \times 30 \times 20$  cm was seen occupying the whole of the abdomen (Fig. 3). Mass was adherent to lateral pelvic walls (Fig. 4), omentum and extending into left inguinal canal and was removed *in toto* (Figs 5 and 6) and weighed 3.8 kgms (Figs 7 and 8). The bowel was free of tumor.

Right and left hemidiaphragm, liver, splenic flexure, stomach were palpated and appeared free from disease. Pelvic congestion and edema were also seen.

Infracolic omentectomy, appendectomy, and bilateral ureteric dissection were done.

Two units of packed cell volume were transfused and the patient was managed in intensive care unit for 2 days. Postoperatively, the patient recovered well. Histopathological analysis was suggestive of leiomyosarcoma, Fédération Nationale des Centres de Lutte Contre le Cancer grade III with no lymphovascular invasion,



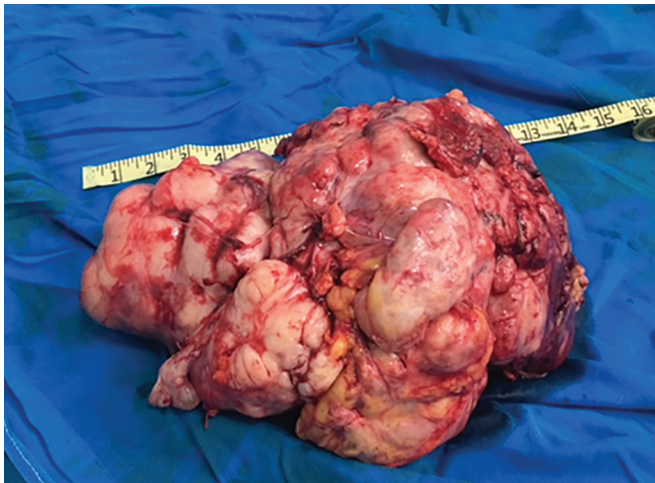


Fig. 6: Mass removed *in toto*

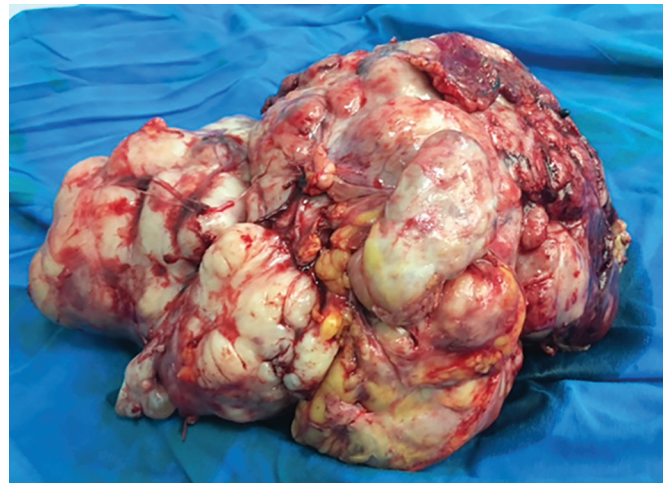

Fig. 7: Solid mass weighing 3.8 kgs

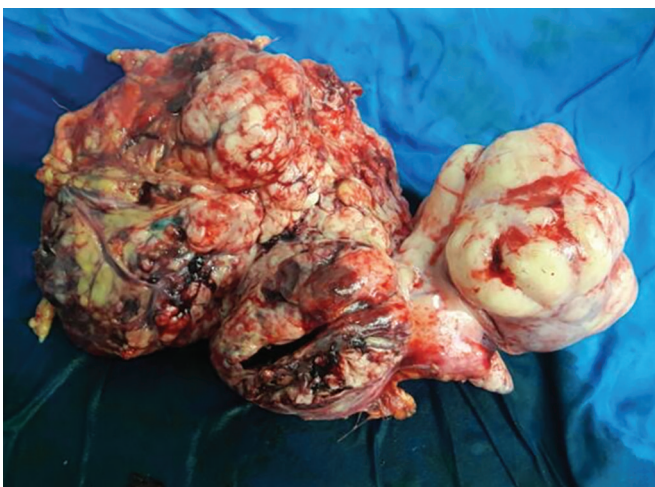

Fig. 8: Large solid mass

attached ovary not involved by tumor, omentum, pelvic peritoneum, and appendix uninvolved by tumor.

The patient was advised radiation and is on regular follow-up with the oncosurgeon.

## DISCUSSION

A recent study showed that there is a small probability of unexpected malignancies incorrectly prescreened patients for laparoscopic hysterectomy procedures. In this study, in 0.25% of the patients having a laparoscopic hysterectomy, an unexpected malignancy was found by histological analysis of the tissue obtained by surgery. About 50% of these unexpected malignancies were found to be a leiomyosarcoma.<sup>2</sup>

Recently, a case has been reported describing disseminated peritoneal leiomyosarcoma shortly after laparoscopic myomectomy with morcellation.<sup>3</sup>

The case was reported where a woman had an unexpected leiomyosarcoma 4 years after the removal of the uterus without any macroscopic intra-abdominal metastasis.<sup>4</sup>

As our case showed, the possibility of leiomyosarcoma should always be considered in case of a suspected tumor in the lower abdomen, even after previous removal of the uterus.

## REFERENCES

1. Hensley ML, Barrette BA, Baumann K, Gaffney D, Hamilton AL, Kim JW, Maenpaa JU, Pautier P, Siddiqui NA, Westermann AM, et al. Gynecologic Cancer InterGroup (GFIG) consensus review: uterine and ovarian leiomyosarcomas. *Int J Gynecol Cancer* 2014 Nov;24(9 Suppl 3): S61-S66.
2. Theben JU, Schellong ARM, Altgassen C, Kelling K, Schneider S, Große-Drieling D. Unexpected malignancies after laparoscopic-assisted supracervical hysterectomies (LASH): an analysis of 1,584 LASH cases, *Arch Gynecol Obstet* 2013 Mar;287(3):455-462.
3. Anupama R, Ahmad SZ, Kuriakose S, Vijaykumar DK, Pavithran K, Seethalekshmy NV. Disseminated peritoneal leiomyosarcomas after laparoscopic 'myomectomy' and morcellation. *J Minim Invasive Gynecol* 2011 May-Jun;18(3):386-389.
4. Prins JR, Van Oven MW, Helder-Woolderink JM. Unexpected leiomyosarcoma 4 years after laparoscopic removal of the uterus using morcellation. *Case Rep Obstet Gynecol* 2015;2015:723606.